

## Anesthesia for Cesarean Section in a Patient with Asherman's Syndrome

CHARLES E. SMITH, M.D.,\* SALLY K. WEEKS, M.B.†

Asherman's syndrome, first described in 1950,<sup>1-3</sup> is characterized by intrauterine synechiae occurring after postpartum or postabortal curettage. This often results in adherence of the anterior and posterior uterine walls with partial or complete obliteration of the uterine cavity.<sup>4-6</sup> Severe obstetrical complications may occur in this group of patients, including prematurity, neonatal death, spontaneous abortion, abnormal presentation, placenta accreta, uterine sacculation, paper-thin uterus (uterine dehiscence), ectopic pregnancy, and placenta previa.<sup>7-17</sup>

We report a case of Asherman's syndrome complicated by placenta accreta and cervico-isthmic pregnancy in a parturient undergoing elective cesarean section for breech presentation.

## REPORT OF A CASE

A 42-yr-old woman, gravida 3, para 1, aborta 1, was admitted at 41 weeks gestation with a history of infertility since the birth of her only child 12 yr earlier. At that occasion, she was delivered by forceps under epidural anesthesia of a live male infant weighing 2535 gm at 37 weeks gestation. Five years prior to the present admission, she had a spontaneous abortion at 12 weeks gestational age, followed by curettage for retained products. She smoked 1½ packs of cigarettes per day for 15 yr, and 15 cigarettes per day during this pregnancy. There were no other medical problems or history of anesthetic complications. Physical examination revealed a healthy 75 kg, 168 cm female. Arterial blood pressure was 110/70 mmHg, heart rate 80 bpm, respirations 20 breaths per minute, and temperature 36.6°C. The uterus was gravid with irregular masses suggestive of fibroids. Ultrasound examination at 40 weeks revealed moderate oligohydramnios and a live infant in the breech presentation. Laboratory results were: hemoglobin 14.4 gm/dl, prothrombin and partial thromboplastin times normal, and platelets 214,000/mm<sup>3</sup>. Serum electrolytes, glucose, blood urea, and urinalysis were normal.

An elective cesarean section was planned because of the patient's age, long period of infertility, and breech presentation. As there was no mention of obstetric problems in the history, epidural anesthesia was discussed with the patient and the risks explained. It was learned during surgery, however, that a diagnosis of Asherman's syndrome

had been made 6 yr earlier on the basis of the history and radiologic evidence of intrauterine synechiae.

After application of a blood pressure cuff, EKG, pulse oximeter, and 16-gauge intravenous cannula, a lumbar epidural catheter was inserted at the L2-L3 interspace. A T4 block was established with 18 cc of 2% carbonated lidocaine and 1/200,000 epinephrine in increments *via* the epidural catheter. Oxygen, 6 liters per minute, was administered *via* a plastic face mask. A normal, healthy live girl (Apgars 8 and 9 at 1 and 5 min), weighing 3100 gm, was extracted easily, but the surgeon was unable to deliver the placenta. The uterus was exteriorized, and it was then realized that the entire pregnancy had been in the cervix and lower uterine segment (fig. 1). The small uterine fundus was not dilated, and was sitting on top of the lower expanded uterine segment. The placenta was densely adherent to the upper pole, so that no plane of separation was found. Arterial blood pressure decreased to 60 mmHg systolic, but apparent blood loss was not excessive. Heart rate was 100 bpm, oxygen saturation 99%, and the patient felt dizzy and nauseated. A decision was made to perform an emergency hysterectomy. A 14-gauge cannula was inserted, and 2 liters 0.9% saline were administered with 15 mg of ephedrine iv. A syntocinon infusion was started. Arterial blood pressure increased to 90/60 mmHg within 5 min, heart rate decreased to 85 bpm, oxygen saturation was 98%, and the patient's symptoms improved. Diazepam 10 mg was administered iv in 2.5-mg increments. Prior to skin closure, 50 µg of fentanyl diluted in 10 cc 0.9% saline was given *via* the epidural catheter for postoperative analgesia. A total of 5.0 l of crystalloid and 0.5 l of hetastarch was administered to maintain stable vital signs. Cesarean hysterectomy was uneventful, and the patient was taken to the recovery room in good condition after a total surgical time of 2 h. The estimated blood loss was 1.5 liters, and a blood transfusion was not required.

On the first postoperative day, the hemoglobin was 10 gm/dl. The patient was discharged home on the seventh postpartum day with no adverse sequelae.

## DISCUSSION

Asherman's syndrome, or traumatic intrauterine synechiae, most often follows postpartum or postabortal curettage.<sup>2</sup> The presenting symptoms include amenorrhea, hypomenorrhea, dysmenorrhea, and recurrent abortions, but the most common symptom is infertility.<sup>12</sup> The diagnosis is often confirmed by hysterosalpingography and hysteroscopy.<sup>18</sup> The obstetrical treatment is relatively simple: surgical lysis of adhesions, and restoration of cervical and uterine patency.<sup>19,20</sup> This results in pregnancy in about 50% of cases.<sup>10</sup> However, such pregnancies may have a high incidence of complications, the most serious and feared being postpartum and antepartum hemorrhage due to accretion of the placenta<sup>21</sup> and cervical pregnancy,<sup>22</sup> respectively.

The term placenta accreta refers to all conditions in which the placenta adheres to, invades, or penetrates

\* Assistant Professor of Anesthesia.

† Associate Professor of Obstetrics and Anesthesia.

Received from the Royal Victoria Hospital and McGill University, Department of Anaesthesia, Montreal, Canada. Accepted for publication October 29, 1987.

Address reprint requests to Dr. Smith: Department of Cardiothoracic Anesthesia, The Cleveland Clinic Foundation, 9500 Euclid Avenue, Cleveland, Ohio 44106.

Key words: Asherman's syndrome. Surgery: obstetric.

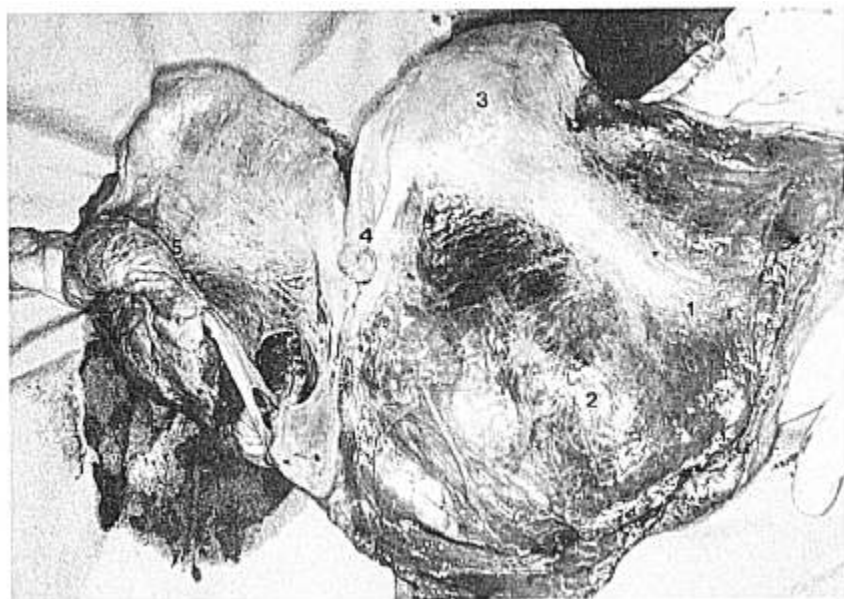


FIG. 1. Anterior view of the excised specimen. The cervical and lower uterine segments are distended (1) and contain the placenta accreta (2). The uterine fundus (3) is contracted above the lower segment. The right fallopian tube and round ligament are shown (4), as well as the cut posterior segment of the placenta (5).

through the myometrium.<sup>17</sup> The layer of decidua which normally separates the placental villi and the myometrium at the site of implantation is absent.<sup>17,23</sup> Although the exact cause is unknown, abnormal adherence of the placenta is found most often in circumstances that predispose to defective decidual formation, such as previous cesarean section, placenta previa, grand multiparity, and previous uterine curettage.<sup>24</sup> Estimates of the incidence of placenta accreta vary from 1 in 2000 to 1 in 7000 deliveries.<sup>25</sup> The incidence of placenta accreta after treatment of Asherman's syndrome is unknown, but appears to be high, ranging from 23 to 40% of deliveries.<sup>7,10,12,26-29</sup> Forssman<sup>10</sup> reviewed 167 pregnancies after a diagnosis of Asherman's syndrome had been made. Of the 60 that resulted in living children, 14 (23.3%) had placenta accreta, and two (3.3%) had placenta previa. The outcome of 148 pregnancies in patients with Asherman's syndrome has been summarized from 1965-75:<sup>7</sup> Of the 70 that reached term, 19 (27%) had placenta accreta. Fox<sup>23</sup> reviewed 622 cases of placenta accreta from 1945-1969 and found that 30.2% of all cases occurred in women who previously underwent uterine curettage. The diagnosis of placental accretion is usually established when hemorrhage becomes profuse during attempted delivery of the placenta.<sup>24,25</sup> Removal of an extensively adherent placenta is very difficult, and may cause uterine inversion or rupture accompanied by sudden, massive hemorrhage.<sup>30</sup> Successful treatment depends upon immediate fluid and blood replacement, and nearly always requires emergency cesarean hysterectomy.<sup>24,31</sup> The overall maternal mortality in patients with placenta accreta (622 cases treated between 1945-1969) was 10% due to

hemorrhage, shock, ruptured uterus, or cardiac arrest.<sup>23</sup>

A close association between cervical pregnancy and Asherman's syndrome has been documented by several investigators.<sup>22,32,33</sup> This rare form of ectopic pregnancy in which implantation of the ovum occurs at the cervical isthmus, or even within the cervix itself, rarely goes beyond the 20th week of gestation, and is usually terminated surgically because of antepartum hemorrhage.<sup>34,35</sup> However, our patient carried to term and did not bleed prior to delivery, despite implantation of the entire products of conception in the cervico-isthmic and lower uterine regions. Although the mortality rate from cervical pregnancy has declined through the years from 45% in 1911<sup>34</sup> to 30% in 1945<sup>36</sup> and 6% in 1953,<sup>37</sup> severe maternal morbidity may still occur as a result of shock from persistent bleeding following attempts at removal of the placenta vaginally (curettage), or to delayed hysterectomy.

Traumatic intrauterine synechiae, although relatively rare, is, thus, of serious concern to the anesthesiologist. Pregnancy following a diagnosis of Asherman's syndrome should be considered hazardous. If a diagnosis of placenta accreta, placenta previa, or cervical pregnancy has been confirmed and the patient is actively bleeding, emergency cesarean section under general anesthesia should be performed immediately.<sup>24,25,31</sup> Rapid intravenous infusion of crystalloid, colloid, or blood solutions through at least two large bore ivs (16 gauge or larger) is the most effective means of restoring adequate circulating volume in an attempt to maintain tissue oxygenation.<sup>38</sup> It may not be possible to correct the massive blood loss completely until the obstetrician has removed

the placenta.<sup>31</sup> Placenta accreta will be almost impossible to remove because of its adherence to the uterine wall, and bleeding will worsen with each attempt at removal.<sup>24,38</sup> Therefore, this diagnosis will usually mandate emergency cesarean hysterectomy.<sup>24,30,39</sup> Removal of the highly vascular gravid uterus may entail substantial blood loss.<sup>38</sup> Although major conduction anesthesia (spinal, lumbar epidural) with its accompanying widespread sympathectomy is highly unlikely to be initiated *de novo* in a bleeding patient, we feel that regional anesthesia is relatively contraindicated in a non-bleeding term parturient with Asherman's syndrome because of the 23–40% risk of placenta accreta. Although the advantages of regional anesthesia in terms of intact airway reflexes, awake patient, favorable intrauterine environment, and less pressure on the obstetrician to deliver the fetus rapidly<sup>40</sup> are recognized, we feel that the possibility of rapid, severe, major hemorrhage dictates against this technique. Although the outcome of our patient was favorable (cesarean section was performed electively for breech presentation in a hemodynamically stable patient), resuscitation of an awake, nauseated, distressed parturient with hemorrhagic shock during epidural anesthesia may be difficult. General anesthesia with large bore ivs may be urgently required, and cross-matched blood should be readily available. In addition, the neonate may be asphyxiated, acidotic, and hypovolemic, and may require intensive resuscitation at birth.<sup>31</sup>

The authors wish to thank Dr. D. R. Bevan for his useful criticisms during the preparation of this manuscript.

#### REFERENCES

1. Asherman JG: Traumatic intrauterine adhesions. *J Obstet Gynaecol Br Emp* 57:892–896, 1950
2. Asherman JG: Traumatic intrauterine adhesions and their effect on fertility. *Int J Fertil* 2:49–61, 1957
3. Asherman JG: The myth of tubal and endometrial transplantation. *J Obstet Gynaecol Br Emp* 67:228–233, 1960
4. Schenker JG, Margalioth EJ: Intrauterine adhesions: An updated appraisal. *Fertil Steril* 37:593–610, 1982
5. Klein SM, Garcia CR: Asherman's syndrome: A critique and current review. *Fertil Steril* 24:722–735, 1973
6. Bergman P: Traumatic intrauterine lesions. *Acta Obstet Gynecol Scand* 40(Suppl 4):1–39, 1961
7. Jewelewicz R, Khalaf S, Neuwirth RS, VandeWiele RL: Obstetric complications after treatment of intrauterine synechiae (Asherman's syndrome). *Obstet Gynecol* 47:701–705, 1976
8. Friedman A, Defazio J, Decherney A: Severe obstetric complications after aggressive treatment of Asherman's syndrome. *Obstet Gynecol* 67:864–867, 1986
9. Beard RM: Placenta accreta in a patient with Asherman's syndrome. *Aust NZ J Obstet Gynaecol* 6:316–319, 1966
10. Forssman L: Posttraumatic intrauterine synechiae and pregnancy. *Obstet Gynecol* 26:710–713, 1965
11. Dmowski WP, Greenblatt RB: Asherman's syndrome and risk of placenta accreta. *Obstet Gynecol* 34:288–299, 1969
12. Georgakopoulos P: Placenta accreta following lysis of uterine synechiae (Asherman's syndrome). *J Obstet Gynaecol Br Commonw* 81:730–733, 1974
13. Jauchler GW, Baker RL: Cervical pregnancy: Review of the literature and a case report. *Obstet Gynecol* 35:870–874, 1970
14. Burry KA, Veltman L: Postpartum conglutination of the lower uterine segment following a placenta previa. Asherman's syndrome revisited. *J Reprod Med* 24:48–50, 1980
15. Bevan JR, Marley NJE, Ozumba EN: Uterine rupture, placenta percreta and curettage in early pregnancy. *Br J Obstet Gynaecol* 92:642–644, 1985
16. Parente JT, Chau-Su O, Levy J, Legatt E: Cervical pregnancy analysis: A review and report of five cases. *Obstet Gynecol* 62:79–82, 1983
17. Hutton L, Yang SS, Bernstein J: Placenta accreta: A 26-year clinicopathologic review (1956–1981). *New York State J Med* 83:857–869, 1983
18. Confino E, Friberg J, Giglia RT, Gleicher N: Sonographic imaging of intrauterine adhesions. *Obstet Gynecol* 66:596–598, 1985
19. Sanfilippo JS, Fitzgerald MJ, Badawy SZA, Nussbaum ML, Yussman MA: Asherman's syndrome: A comparison of therapeutic methods. *J Reprod Med* 27:328–330, 1982
20. Ismajovich B, Lidor A, Confino E, David MP: Treatment of minimal and moderate intrauterine adhesions (Asherman's syndrome). *J Reprod Med* 30:769–772, 1985
21. Foix A, Brund RO, Davison T, Lema B: The pathology of postcurettage. *Am J Obstet Gynecol* 96:1027–1033, 1966
22. Rothe DJ, Birnbaum SJ: Cervical pregnancy: Diagnosis and management. *Obstet Gynecol* 42:675–680, 1973
23. Fox H: Placenta accreta, 1945–1969. *Obstet Gynecol Surv* 27:475–490, 1972
24. Pritchard JA, MacDonald PC, Gant NF: *Williams Obstetrics*. Connecticut, Appleton-Century Crofts, 1985, pp 707–718
25. Kapernick PS: Postpartum hemorrhage and the abnormal puerperium, *Current Obstetric & Gynecologic Diagnosis & Treatment*. Edited by Pernoll ML, Benson RC. Connecticut, Appleton & Lange, 1987, pp 524–540
26. Cominos AC, Zourlas PA: Treatment of uterine adhesions (Asherman's syndrome). *Am J Obstet Gynecol* 105:862–868, 1969
27. Jensen PA, Stromme WB: Amenorrhea secondary to puerperal curettage (Asherman's syndrome). *Am J Obstet Gynecol* 113:150–154, 1971
28. Behrman SJ: Asherman's syndrome: A critique and current review. *Fertil Steril* 24:736–737, 1973
29. Oelsner G, David A, Insler V, Serr DM: Outcome of pregnancy after treatment of intrauterine adhesions. *Obstet Gynecol* 44:341–344, 1974
30. Kelly JV: Postpartum hemorrhage. *Clin Obstet Gynecol* 19:595–604, 1976
31. Biehl DR: Antepartum and postpartum hemorrhage, *Anesthesia for Obstetrics*. Edited by Shnider SM, Levinson G. Baltimore, Williams & Wilkins, 1987, pp 281–289
32. Shinagawa S, Nagayama M: Cervical pregnancy as a possible sequela of induced abortion. Report of 19 cases. *Am J Obstet Gynecol* 105:282–284, 1969
33. Dicker D, Feldberg D, Samuel N, Goldman JA: Etiology of cervical pregnancy. Association with abortion, pelvic pathology, IUDs and Asherman's syndrome. *J Reprod Med* 30:25–27, 1985
34. Rubin IC: Cervical pregnancy. *Surg Gynecol Obstet* 13:625–633, 1911

35. David MP, Bergman A, Delighdish L: Cervico-isthmus pregnancy carried to term. *Obstet Gynecol* 56:247-252, 1980
36. Studdiford WE: Cervical pregnancy: A partial review of the literature and a report of two probable cases. *Am J Obstet Gynecol* 49:169-185, 1945
37. Baptisti A: Cervical pregnancy. *Obstet Gynecol* 1:353-358, 1953
38. Plumer MH: Bleeding problems, *Obstetric Anesthesia: The Complicated Patient*. Edited by James FM, Wheeler AS. Philadelphia, FA Davis Co, 1982, pp 185-207
39. Clark SL, Yeh S, Phelan JP, Bruce S, Paul RH: Emergency hysterectomy for obstetric hemorrhage. *Obstet Gynecol* 64:376-380, 1984
40. Shnider SM, Levinson G: *Anesthesia For Obstetrics*. Baltimore, Williams & Wilkins, 1987, pp 159-178

Anesthesiology  
68:618-621, 1988

## Intravenous Lidocaine Reduces the Incidence of Vomiting in Children after Surgery to Correct Strabismus

LOUISE O. WARNER, M.D.,\* GARY L. ROGERS, M.D.,† J. DAVID MARTINO, M.D.,‡  
DON L. BREMER, M.D.,§ THOMAS P. BEACH, M.D.¶

One of the authors (GLR) noticed that the incidence and severity of vomiting after surgery to correct strabismus had decreased in the past few years. The turn-about seemed to coincide with a change in anesthetic technique: the routine administration of iv lidocaine in place of succinylcholine to facilitate endotracheal intubation for short procedures during halothane anesthesia.

We had initially utilized lidocaine to treat—and, subsequently, to prevent—dysrhythmias generated by succinylcholine and airway instrumentation in lightly anesthetized children. Eventually, we realized that tracheal intubating conditions in most patients receiving lidocaine iv without succinylcholine were excellent.

We compared randomly chosen records of 50 patients from 1979 who had had surgery to correct strabismus, and who had received succinylcholine to facilitate intubation of the trachea, to the records of 50 similar patients in 1986 who had received lidocaine instead of succinylcholine. We found that the incidence of postoperative emesis had decreased from 54% to 28%. However, there were enough other variables to warrant a controlled study to substantiate this observation, which is described below.

bismus, and who had received succinylcholine to facilitate intubation of the trachea, to the records of 50 similar patients in 1986 who had received lidocaine instead of succinylcholine. We found that the incidence of postoperative emesis had decreased from 54% to 28%. However, there were enough other variables to warrant a controlled study to substantiate this observation, which is described below.

### MATERIALS AND METHODS

The Human Subjects Research Committee approved our project, and each parent/guardian signed a consent form. The subjects were limited to ASA I outpatients undergoing surgery to correct strabismus, aged 18 months through 7 yr. Seventy-five consecutive children who met study criteria were randomized into three groups of 25 by using sealed envelopes: group I received lidocaine, 2 mg/kg, 90 s prior to laryngoscopy; group II received iv succinylcholine, 1 mg/kg, 1 min prior to laryngoscopy; group III received both lidocaine and succinylcholine (same doses and timing). Group III was added to determine if succinylcholine would negate any proposed positive effect from lidocaine.

All received an oral solution containing 0.02 mg/kg of atropine sulfate, 0.75 mg/kg of promethazine, and 25 mg/kg of chloral hydrate 1 h before surgery. Anesthesia was induced with a halothane (2.5%)-nitrous oxide (70%)-oxygen mixture; drugs used to facilitate tracheal intubation were administered when the child reached a light surgical plane. Respirations were assisted in all, and then controlled with the onset of paralysis in the two groups receiving succinylcholine. All children were hyperventilated for several seconds just prior to laryngoscopy: this was necessary in the "lidocaine only" group to abolish inherent respiratory drive during laryngoscopy and tracheal intubation. Anesthesia was maintained with a halothane (1.5-2%)-nitrous

\* Clinical Assistant Professor, Ohio State University College of Medicine; Director of Anesthesia Research, Children's Hospital.

† Clinical Associate Professor, Ohio State University College of Medicine; Chief, Department of Ophthalmology, Children's Hospital.

‡ Clinical Assistant Professor, Ohio State University College of Medicine; Attending Staff, Department of Anesthesiology, Children's Hospital.

§ Associate Professor, Ohio State University College of Medicine; Attending Staff, Department of Ophthalmology, Children's Hospital.

¶ Clinical Associate Professor, Ohio State University College of Medicine; Chief, Department of Anesthesiology, Children's Hospital.

Received from the Ohio State University College of Medicine, Columbus, Ohio; and the Departments of Ophthalmology and Anesthesiology, Children's Hospital, Columbus, Ohio. Accepted for publication November 2, 1987. Presented in part at the meeting of the American Association of Pediatric Ophthalmology and Strabismus, Phoenix, Arizona, March, 1987; and at the meeting of the American Academy of Pediatrics, San Francisco, California, May, 1987. Work was performed at Children's Hospital.

Address reprint requests to Dr. Warner: Department of Anesthesiology, Children's Hospital, 700 Children's Drive, Columbus, Ohio 43205.

Key words: Anesthetics, local: lidocaine. Surgery: strabismus. Vomiting: incidence.